

# Case Report: Penetrating Cardiac Injury Secondary to a Terrorism-Related Nail Bomb Explosion

Yasufumi Asai, MD;<sup>1</sup> Masashi Yoshida, MD;<sup>2</sup> Yoshihiko Kurimoto, MD;<sup>2</sup> Jeffrey L. Arnold, MD<sup>3</sup>

1. Chairman, Department of Traumatology and Critical Care Medicine, Sapporo Medical University, Sapporo, Japan
2. Department of Traumatology and Critical Care Medicine, Sapporo Medical University, Sapporo, Japan
3. Office of Emergency Preparedness, Yale New Haven Center for Emergency and Terrorism Preparedness, Yale New Haven Health System, New Haven, Connecticut USA

**Correspondence:**

Yasufumi Asai, MD  
Department of Traumatology and Critical Care Medicine  
Sapporo Medical University  
E-mail: asai@sapmed.ac.jp

**Keywords:** bombing; cardiac injury; explosion; myocardial infarction; nail bomb; penetrating cardiac injury; pericardial tamponade; terrorism

**Abbreviations:**

ED = Emergency Department  
EMS = Emergency Medical Services  
POD = postoperative day

**Web publication:** 15 March 2004

**Abstract**

Penetrating cardiac injuries commonly occur secondary to gunshot or stab wounds. This is a report of an unusual case of a patient who sustained a penetrating cardiac injury due to a nail from a terrorism-related, nail-bomb explosion. Associated problems included pericardial tamponade, penetrating cardiac injuries, acute, traumatic, myocardial infarction, and a penetrating lung injury. Prompt diagnosis and aggressive surgical intervention resulted in full recovery of the patient.

Asai Y, Yoshida M, Kurimoto Y, Arnold JL: Case report: Penetrating cardiac injury secondary to terrorism-related, nail-bomb explosion. *Prehosp Disast Med* 2003;18(3):249–252.

**Case Report**

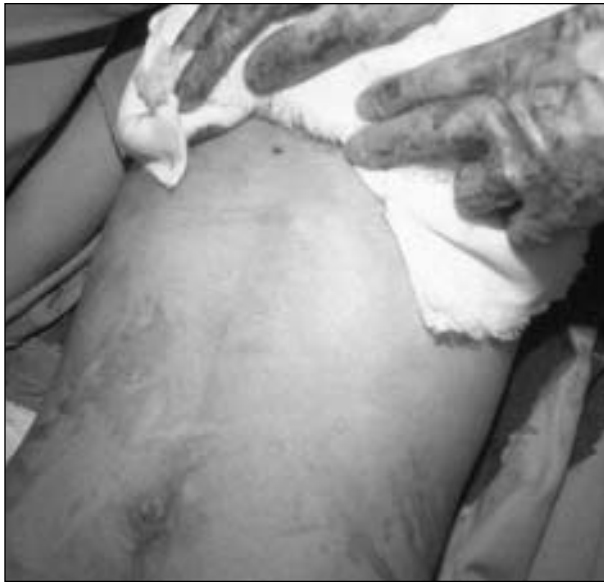A previously healthy, 18 year-old, male student was injured from a terrorism-related explosion that occurred while he was sorting garbage as a festival volunteer on the evening of 10 June 2000 at the 9th Yosakoi-Sohran Festival at Odori Park in Sapporo, Japan. The bomb, which had been placed in a trash receptacle, exploded at 22:35 hours (h).

A 1-1-9 emergency call was placed to Emergency Medical Services (EMS) at 22:40 h, and the first ambulance arrived at 22:45 h. At the scene, the patient, who was the closest person to the explosion, complained of chest pain and shortness of breath, but had no visible injuries. His systolic blood pressure was 80 mmHg, heart rate was 60 beats per minute, and ventilatory rate was 20 breaths per minute. Eight other persons suffered minor injuries; five had at least one perforated tympanic membrane, two had unspecified contusions, and one had a hip abrasion.

The patient was transported from the scene by ambulance at 23:00 h. On arrival at the emergency department (ED) at Sapporo Medical University Hospital at 23:04 h, he

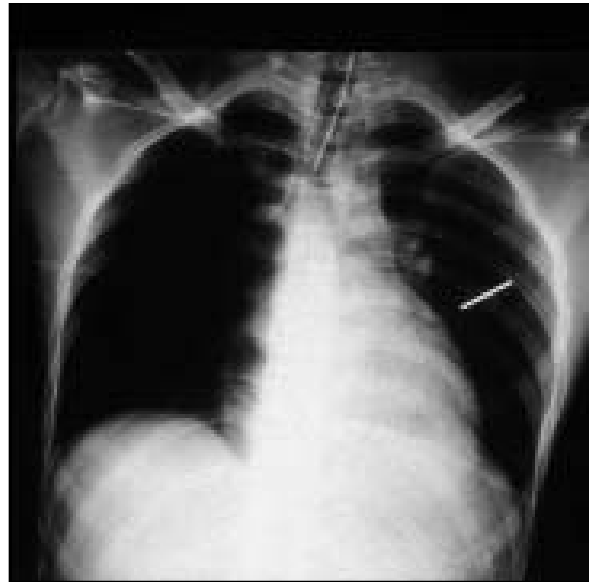
continued to complain of anterior chest pain and shortness of breath. He was agitated and diaphoretic. His blood pressure was 80/62 mmHg, his heart rate was 52 beats per minute, respiratory rate was 20 breaths per minute, and his oxygen saturation was 90% on supplemental oxygen. Neck veins were distended. There was no subcutaneous emphysema, and breath sounds were normal bilaterally. Peripheral pulses were weak, and heart sounds were distant. A 3 mm diameter, circular wound was present just below his xiphoid process (Figure 1). His abdomen was not distended and was non-tender. The remainder of his physical examination was unremarkable. A chest radiograph showed a pointed, foreign body, consistent with a nail, in the left mid lung field (Figures 2 and 3). An electrocardiogram showed a sinus bradycardia with 2 mm S-T segment elevation across the precordium and in leads II, III, and aVF.

One hour after admission, he became hypotensive and tachycardic, and then, suffered a cardiac arrest. He immediately received cardiopulmonary resuscitation, including



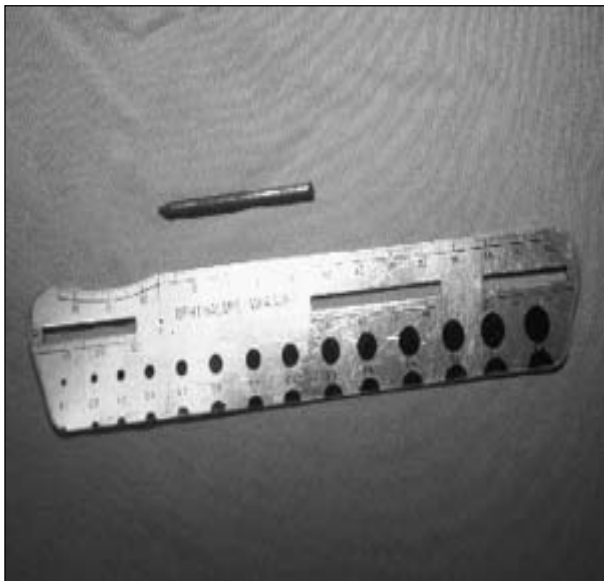Prehospital and Disaster Medicine © 2003 Asai

**Figure 1**—Photograph of the patient's abdomen showing a small subxiphoid entry wound



Prehospital and Disaster Medicine © 2003 Asai

**Figure 2**—Chest radiograph showing a nail embedded in the patient's left lung



Prehospital and Disaster Medicine © 2003 Asai

**Figure 3**—Photograph of the 5 cm headless nail removed from the patient's left lung

endotracheal intubation and 3.5 liters of crystalloid solution intravenously. A bedside echocardiogram revealed a 1.5 cm pericardial fluid collection and globally decreased wall motion consistent with pericardial tamponade. Pericardiocentesis was performed using a 14 French gauge catheter and 200 ml of blood was evacuated. Although his systolic blood pressure increased to 100 mmHg, his bradycardia persisted, and he again suffered a cardiopulmonary arrest. An emergency thoracotomy was performed in the emergency department (ED) using a clamshell incision. Pericardiotomy revealed a large hemopericardium, which was

evacuated, and the pericardiocentesis catheter obstructed by a clot. Two minutes after his cardiopulmonary arrest, spontaneous cardiac activity resumed. However, hemorrhage from his cardiac wounds could not be controlled, and his condition remained unstable despite aggressive volume resuscitation with the administration intravenous crystalloid solutions and blood transfusions.

He was brought to the operating room with a systolic blood pressure of 30 mmHg, where he underwent standard sternotomy followed by cardiopulmonary bypass. Two wounds to his heart were identified: a 2 mm entrance wound on the anterior wall of the right ventricle, and a 2 mm exit wound on the posterior wall of the left ventricle, which penetrated his left circumflex coronary artery. Each wound was closed with a single stitch using a felt-strip suture. A 5 cm long nail was enucleated from his left lung in a retrograde manner. The nail head appeared to have been removed.

At the end of the operation, the patient was weaned from the cardiopulmonary bypass, and he was taken to the surgical intensive care unit in stable condition. He was extubated on postoperative day (POD) 2. His cardiac function gradually recovered as assessed using daily echocardiography, and he began to walk on POD 9. A coronary angiogram on POD 21 showed a 50% stenosis of segment #14 of his left circumflex coronary artery. Cardiac wall motion was normal, and no ventricular-septal defect was present. The patient was discharged on POD 35 without significant cardiac dysfunction.

### Discussion

This is the first case reported in the medical literature, in which a penetrating cardiac injury from a terrorism-related explosion was treated successfully. A MEDLINE search using an OVID interface and the key words "cardiac injury" OR "penetrating cardiac injury" AND "explosion" OR "bombing". Only two other reports of penetrating cardiac

injuries in survivors of explosions were found. McKain *et al* reported a case of a 13 year old who survived a penetrating injury of his right ventricle from a metal pen top while detonating a home-made rocket propelled by gun powder.<sup>1</sup> Catipovic-Veselica *et al* reported five patients who survived penetrating cardiac injuries due to shrapnel from explosive devices during war.<sup>2</sup>

Although the perpetrator(s) of this explosion has yet to be apprehended, this event had a number of characteristics consistent with terrorism. Terrorists frequently target high-profile events of symbolic or commercial importance in a community, e.g., the 1987 Remembrance Day bombing in Enniskillen and the 1997 Olympic Park bombing in Atlanta.<sup>3,4</sup> The Yosakoi-Sohran Festival is such an event, bringing >40,000 participants and 1.5 million spectators to Sapporo each June over five days.<sup>5,6</sup> Recently, the Yosakoi-Sohran Festival eclipsed the Sapporo Snow Festival as the largest celebration in Hokkaido, the northern-most island in Japan. Prior to the opening of the Festival, the organizers had received an anonymous e-mail that warned them if the Festival was not cancelled, it would be bombed.

Terrorists also conceal bombs in innocuously appearing delivery systems, such as trash receptacles, backpacks, suitcases, etc., not only to evade detection, but also to increase physical and psychological injuries.<sup>4,7,8</sup> Terrorists also are known to combine the explosive materials with metal additives in order to potentiate the number and severity of injuries.<sup>4,9-12</sup> The explosive device used here later was determined to be a crude nail-bomb, consisting of a paper bag packed with gunpowder and nails. The morning after the bombing, police investigators found several headless nails scattered about the scene of the bombing, underscoring the meticulousness with which this bomb was prepared.

A nail-bomb is a small magnitude explosive device packed with nails, which, on detonation, produces primary blast injuries from the blast wave, low-velocity penetrating injury due to flying nails or casing fragments, and flash burns due to the blast heat.<sup>13</sup> In the current case, no other metal shrapnel was generated, because the explosive material was packed into a paper bag. A small amount of explosive material was in this bomb, as was suggested by the absence of other blast injuries and the relatively minor injuries sustained by the other eight victims.

The injuries sustained by the current patient's resembled those due to a nail gun. In nail-gun injuries, the radial kinetic energy of the nail is minimal compared to a conventional bullet, and the blast effects and surrounding tissue damage are limited.<sup>14</sup> In addition, nails have an elongated form with a small frontal, cross-sectional area, which focuses the force of impact into a small area. As a result, cardiac nail-gun injuries have more in common with stab wounds than do penetrating injuries due to bullets, despite their being projectile in nature.<sup>14</sup> Furthermore, tissue damage is proportional to the angle between the long axis of the nail and its flight path.<sup>15</sup> In the current case, a headless nail entered the chest perpendicular to the surface, and the surrounding tissue damage was minimal.

This case also demonstrates the common anatomic features of penetrating cardiac injuries. Penetrating cardiac injuries mostly involve the right ventricle (40%) or left ventricle (30%).<sup>16</sup> Pericardial tamponade occurs in 43% of patients with penetrating cardiac injury(ies); 73% of victims have survived.<sup>17</sup> Coronary artery lacerations are uncommon (5%), and almost always are fatal.<sup>16,18</sup>

### Summary

The current case highlights the importance of careful evaluation of victims of terrorist bombings for the presence of life-threatening penetrating injuries. Although an explosion was reported, the patient did not realize that he had been struck by a projectile. Only after disrobing the patient in the emergency department, was the small innocuous-appearing wound detect that suggested that a penetrating injury had occurred.

Finally, this patient not only survived two cardiopulmonary arrests in the ED, but also a thoracotomy was performed in the ED. Since it is rare for victims of terrorist bombings to die in modern, well-equipped EDs—even when mass casualty numbers of injured survivors are generated—every critically injured survivor that reaches the ED alive, should be considered potentially salvageable until proven otherwise.<sup>19,20</sup>

The experience with this case suggests that the prompt recognition of penetrating cardiac injury in a victim of a terrorism-related explosion and aggressive surgical intervention, including ED thoracotomy when necessary, may result in an optimal outcome.

### References

- McKain JM, Warner GW, Shaub RO: A rocket injury of the heart. Case report. *American Surgeon* 1964;33(9):742-744.
- Catipovi-Veselica K: Penetrating heart wounds repaired without cardiopulmonary bypass. Evaluation and follow-up of recent war injuries. *Tex Heart Inst J* 1993;20(2): 94-98.
- Brown MG, Marshall: The Enniskillen bomb: A disaster plan. *BMJ* 1988;297:1113-1116.
- Feliciano DV, Anderson GV, Rozycki GS, *et al*: Management of casualties from the bombing at the Centennial Olympics. *Am J Surg* 1998;176: 538-543.
- Anonymous. Yasakoi Soran Festival. Yume Gallery Web site. Available at [http://www.ne.jp/asahi/yume/dreams/main/English\\_hokkaido\\_yosakoi.htm](http://www.ne.jp/asahi/yume/dreams/main/English_hokkaido_yosakoi.htm). Accessed 06 August 2003.
- Anonymous: Yasakoi Soran Festival. Available at Hokkaido Government Web site. Available at [http://www.pref.hokkaido.jp/kseikatu/ks-bsbsk/digest/chapter\\_9\\_2.html](http://www.pref.hokkaido.jp/kseikatu/ks-bsbsk/digest/chapter_9_2.html). Accessed 06 August 2003.
- Brismar B, Bergenwald L: The terrorist bomb explosion in Bologna, Italy, 1980: An analysis of the effects and injuries sustained. *J Trauma* 1982; 22:216-220.
- Johnstone DJ, Evans SC, Field RE, Booth SJ: The Victoria bomb: A report from the Westminster Hospital. *Injury* 1993;24:5-9.
- Cudennec YF, Buffe P, Poncet JL: Otologic features and teachings of a bombing attempt. *Mil Med* 1995;160(9):467-470.
- Henderson JV: Anatomy of a terrorist attack: The Cu Chi mess hall incident. *Prehosp Disast Med* 1986;2:69-73.

11. Leibovici D, Gofrit ON, Stein M, *et al*: Blast injuries — Bus versus open-air bombings: A comparative study of injuries in survivors of open-air versus confined-space explosions. *J Trauma* 1996;41:1030–1035.
12. Williams KN, Squires SL: Experience of a major incident alert at two hospitals: "The Soho Bomb". *Br J Anaesth* 2000;85:322–324.
13. Ellis H: Management of nail-bomb injuries. *J R Soc Med* 1983;76:724–725.
14. Vosswinkel J, Bilfinger T: Cardiac nail gun injuries: Lessons learned. *J Trauma* 1999;47:588–590.
15. Alberico G, Bucci I, Ciarelli F, *et al*: An unusual case of nail gun injury: Penetrating neck wound with nail retention in the right pleural cavity. *J Trauma* 1997;43:153–156.
16. Knott-Craig CJ, Przybojewski JZ, Barnard PM: Penetrating wounds of the heart and great vessels—A new therapeutic approach. *South Afr Med J* 1982; 62:316–320.
17. Moreno C, Moore EE, Majune JA, *et al*: Pericardial tamponade. A critical determinant for survival following penetrating cardiac wounds. *J Trauma* 1986;26:821–825.
18. Ivatury RR, Rohman M, Steichen FM, *et al*: Penetrating cardiac injuries: Twenty years experience. *Am Surg* 1987;53:310–317.
19. Arnold JL, Tsai MC, Halpern P, *et al*: Mass casualty terrorist bombings: Epidemiological outcomes, resource utilization, and time course of emergency needs (Part I). *Prehosp Disast Med* 2003;18(3):220–234.
20. Halpern P, Tsai MC, Arnold JL, *et al*: Mass casualty terrorist bombings: Implications for emergency department and hospital emergency response (Part II). *Prehosp Disast Med* 2003;18(3):235–241.