

Pakistan Earthquake: Experiences of a Multidisciplinary Surgical Team

Asim Rajpura, MRCS; Ihab Boutros, MRCS; Tahir Khan, FRCS (T&O);
Sohail Ali Khan, FRCS (T&O)

Department of Orthopedics, Hope Hospital,
Salford, UK

Correspondence:

Mr. Asim Rajpura
6 Manthorpe Ave.
Worsley
Greater Manchester UK
M28 2AZ
E-mail: asimrajpura@gmail.com

No benefits in any form have been received or will be received from a commercial party or individual related directly or indirectly to the subject of this article.

Keywords: earthquake; Ilizarov; Kashmir; limb reconstruction; multidisciplinary; orthopedic; Pakistan; plastic surgery

Abbreviations:

ORIF = open reduction and internal fixation

Received: 12 August 2009

Accepted: 28 September 2009

Revised: 05 October 2009

Web publication: 26 July 2010

Abstract

Introduction: Four weeks after the earthquake in Kashmir, Pakistan, multidisciplinary surgical teams were organized within the United Kingdom to help treat disaster victims who had been transferred to Rawalpindi. The work of these teams between 05–17 November 2005 is reviewed, and experiences and lessons learned are presented.

Methods: Two self-sufficient teams consisting of orthopedic, plastic surgical, anesthetic, and theatre staff were deployed consecutively over a two-week period. A trauma unit was set up in a donated ward within a private ophthalmological hospital in Rawalpindi.

Results: Seventy-eight patients with a mean age of 23 years were treated: more than half (40) were <16 years of age. Fifty-two patients only had lower limb injuries, 18 upper limb injuries, and eight combined lower and upper limb. The most common types of injuries were: (1) tibial fractures (n = 24), with the majority being open grade 3B injuries (n = 22); (2) femoral fractures (n = 11); and (3) forearm fractures (n = 9). Almost half (n = 34) of the fractures were open injuries requiring soft tissue cover.

Over 12 days, 293 operations were performed (average 24.4 per day). A total of 202 examinations under anesthesia, washouts, and debridements were performed. The majority of wounds required multiple washouts prior to definitive procedures. Thirty-four definitive orthopedic procedures (fixations) and 57 definitive plastic procedures were performed. Definitive orthopedic procedures included 15 circular frame fixations of long bones, nine of which required acute shortening and five open reduction and internal fixation of long bones. Definitive plastic procedures included 21 skin grafts, four amputations, 11 revisions of amputations, 20 regional flaps, and one free flap.

Conclusions: A joint ortho-plastic approach was key to the treatment of the spectrum of injuries encountered. Only four patients required fresh amputations. Twenty patients may have required amputation without the use of ring fixators and soft tissue reconstruction. Having self-sufficient teams along with their own equipment and supplies also was mandatory in order not to put further demand on already scarce resources. However, mobilizing such teams logistically was difficult, and therefore, an organization consisting of willing volunteers for future efforts has been established.

Rajpura A, Boutros I, Khan T, Khan SA: Pakistan earthquake: Experiences of a multidisciplinary surgical team. *Prehosp Disaster Med* 2010;25(4):361–367.

Introduction

On 08 October 2005, an earthquake measuring 7.6 on the Richter scale struck the northern areas of Pakistan and India.¹ The epicenter was located approximately 19 km northeast of Muzaffarabad in Pakistan. The North West Frontier Province of Pakistan and Pakistani-administered Kashmir were the most severely affected areas. Relief agency data estimate that >73,000 lives were lost, 128,000 individuals were injured, and >3.5 million people were left homeless.² The earthquake decimated the local infrastructure, with more than 50% of the healthcare facilities in the area being destroyed, and a further 25% damaged.

The scale of the disaster overwhelmed local healthcare systems. Several international agencies such as the International Committee of the Red Cross set up field hospitals in the affected areas to deal with the immediate aftermath of the earthquake.

Four weeks after the earthquake, a team of British orthopedic and plastic surgeons was assembled to assist with the aid effort. The aim was to attempt to limit morbidity and mortality from the complications of the injuries in the survivors, as demonstrated by the third peak in the trimodal distribution of death post-major injury.^{3,4} To date, studies mainly have described the treatment of patients in the immediate aftermath of the earthquake.⁵⁻¹⁰ The experiences from this expedition dealing with the delayed complications of the injuries and highlight lessons learned that could be applied to future efforts are reported.

Methods

Team Composition

The nature of the injuries being reported necessitated a joint ortho-plastic surgical approach. Thus, two teams comprised of two consultant orthopedic surgeons, two senior plastic surgery registrars, two consultant anaesthetists, one junior surgical trainee, two scrub nurses, and one operating department assistant were formed. The teams were deployed for two consecutive weeks starting 05 November 2005. Orthopedic staff chosen for the task had specialist experience in limb reconstruction. The plastic surgeons also were experienced in the management of large soft tissue defects. The teams were formed of staff from northwestern England. They were not part of any coordinated national or international effort.

With the help of a non-governmental organization, the Pakistan Red Crescent Society, and UK-based charity Islamic Help, a makeshift trauma ward and theatre complex had been setup within a privately owned ophthalmological hospital in Rawalpindi, Al Shifa. Basic x-ray and pathology services were available on-site and a mobile theatre x-ray image intensifier was provided by the charitable organization. This was the group's base during the two-week mission. The complex orthopedic, plastic, and anesthetic equipment was donated and/or borrowed from the respective base hospitals in the UK.

The patient population consisted of injured survivors who were transported to the capital from areas near the epicenter. A local sports field was used as a reception facility for these patients. From there, local healthcare teams triaged the patients and 97 patients with limb injuries were sent to the trauma ward. All patients had received basic care in field hospitals set-up in the disaster area.

Documentation regarding their injuries and treatment to date not always was available. Initial tasks included triage and creating basic case records and a database of patients. Patients and injuries were photographed and assigned case note numbers to aid identification and team handover.

All operating was carried out in a theatre complex situated within the makeshift trauma ward. This consisted of an "open plan theatre suite" with three operating tables, each separated by Perspex dividers allowing concurrent operations to take place, a recovery room, instrument sterilization room, chang-

ing room, and an office. A separate dressing clinic also was set up for changes of dressings that did not require anaesthesia. Local anesthetic and scrub staff were available, but staff from the team carried out all operating. A plastic surgical consultant from New Zealand also joined the team for the second week.

Results

Patient Demographics

The mean value for the ages was 23 years (range: 6 months–80 years). More than half ($n = 40$) were <16 years, with 10 patients <5 years. Only eight patients were >60 years old. The age and sex distribution of the patients are in Figure 1. Approximately 60% were female.

Nineteen patients had minor injuries that did not require further management, and therefore, were discharged. These included ankle and upper limb fractures amenable to conservative management with casts. One patient needed transfer to a pediatric intensive care unit due to severe sepsis from extensive muscle necrosis.

Two-thirds of the injuries encountered were lower limb ($n = 52$), 18 upper limb, and eight combined upper and lower limb (Figure 2). The most common injury encountered were tibial fractures ($n = 24$), of which 92% were Gustillo-Anderson grade IIIb (Figure 3). The majority were immobilized in plaster, while others had monolateral external fixators applied. None had received definitive orthopedic fixation or plastic surgical treatment to provide soft tissue cover. All open fractures required multiple washouts and debridement due to infection prior to receiving definitive treatment.

Femoral fractures were the second most common injury encountered, with 64% in children. The four adult femoral fractures had been managed by open reduction and internal fixation (ORIF), three using unlocked Kunscher nails and one with dynamic compression plating. The two pediatric cases who received internal fixation were treated with small fragment dynamic compression plating. These procedures were carried out previously in field hospitals, and therefore, exact details of treatment and management were not available. Two of the fixations were infected. The remaining pediatric femoral fractures had been immobilized in hip spicas. The position of the fractures in hip spicas was not perfect, but accepted at this stage, as callus was visible. Open osteoclasis would have been ideally required, but remodeling was expected.

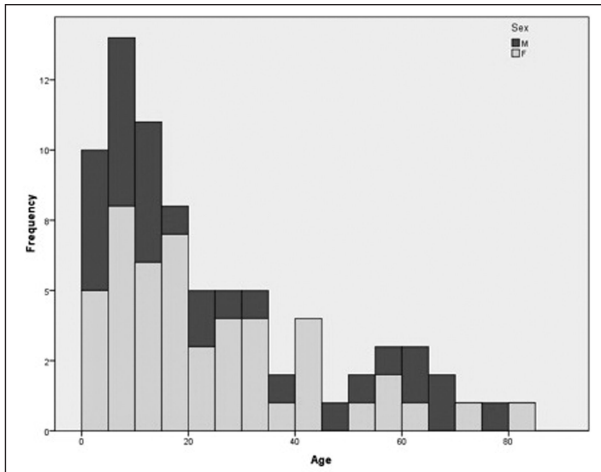
The most common upper limb injuries seen were forearm fractures, followed by humeral and hand injuries. The majority of these (65%) were closed fractures. Examples of open injuries seen included an open Galeazzi fracture, open supracondylar fractures, open mid-shaft humeral and radius/ulna fractures, and open carpal disruptions.

Twelve patients only suffered soft tissue injuries. Examples included an 8-year-old child with truncal burns requiring split skin grafting, and patients with sacral pressure sores and lower limb soft tissue defects.

Overall, almost half ($n = 34$) of the fractures seen were open injuries that required soft tissue cover.

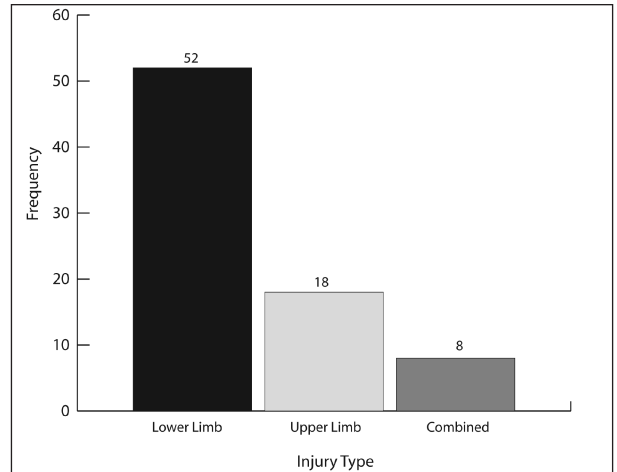
Procedures Performed

A total of 293 procedures were carried out over 12 operating days (average 24.4 per day). The setup of the operating



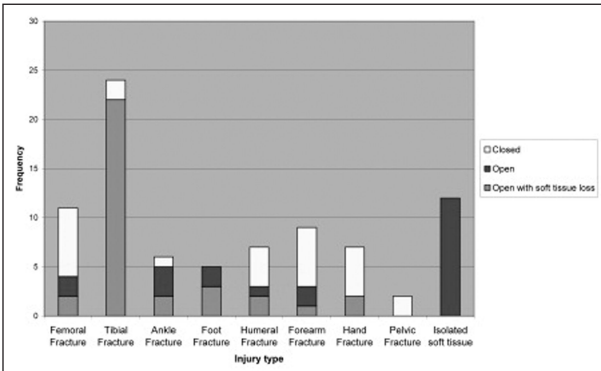
Rajpura © 2010 Prehospital and Disaster Medicine

Figure 1—Distribution of patients by age and sex (Male mean age = 24.9 years; n = 30; Female mean age = 22.9 years; n = 48)



Rajpura © 2010 Prehospital and Disaster Medicine

Figure 2—Injury types encountered



Rajpura © 2010 Prehospital and Disaster Medicine

Figure 3—Injury types encountered (continued)



Rajpura © 2010 Prehospital and Disaster Medicine

Figure 4—Theatre setup

Procedure	Number Performed
Examination under anaesthesia, washouts and debridements	202
Manipulation under anaesthesia	5
Application of Hip Spica	2
K wiring of fractures	7
Open reduction and internal fixation of long bones	5
Circular frame fixation without shortening	6
Circular frame fixation with acute shortening	9
Total number of patients involved	60

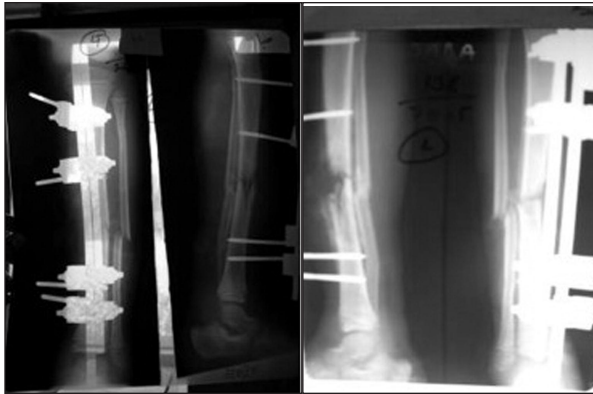
Rajpura © 2010 Prehospital and Disaster Medicine

Table 1—Orthopedic procedures performed

Procedure	Number Performed
Split Skin Grafts	21
Amputation	4
Revision of Amputation	11
Fasciocutaneous Flaps	17
Musculocutaneous Flaps	3 (1 Gastrocnemius, 1 Soleus, 1 Tensor Fascia Lata)
Free Flaps (Rectus)	1
Total number of patients involved	46

Rajpura © 2010 Prehospital and Disaster Medicine

Table 2—Plastic surgical procedures performed



Rajpura © 2010 Prehospital and Disaster Medicine

Figure 5—Left: Initial post-operative x-rays, Right: x-rays taken upon arrival

room allowed three concurrent operations to be carried out with the aid of local anesthetic and scrub staff (Figure 4). This allowed for the high throughput of cases. A breakdown of procedures carried out is in Tables 1 and 2. Thirty-four definitive orthopedic procedures (fixations) and 57 definitive plastics procedures were performed. Nineteen procedures were performed jointly in which fractures were fixed with external fixation followed by skin cover.

Initial work involved repeat debridement of grossly infected open injuries that had been left untreated for four weeks. Definitive procedures were performed on these patients mainly during the second week.

Case 1: Ilizarov and Local Flap

A 6-year-old-girl had been admitted with open mid-shaft left tibial fracture (Figure 5). She had undergone initial debridement and application of a monolateral external fixator prior to transfer to this unit.

Repeat x-rays showed an area of bone loss and osteomyelitis (Figure 5). Examination under anesthesia revealed an 8 x 6 cm soft tissue defect with exposed bone. She underwent repeat debridement and eventual acute shortening after excision of sequestrum. A fasciocutaneous flap then was fashioned out to cover the soft tissue defect and an Ilizarov frame was applied (Figure 6).

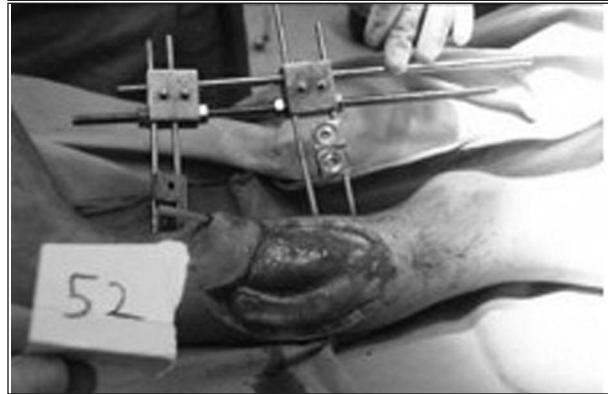
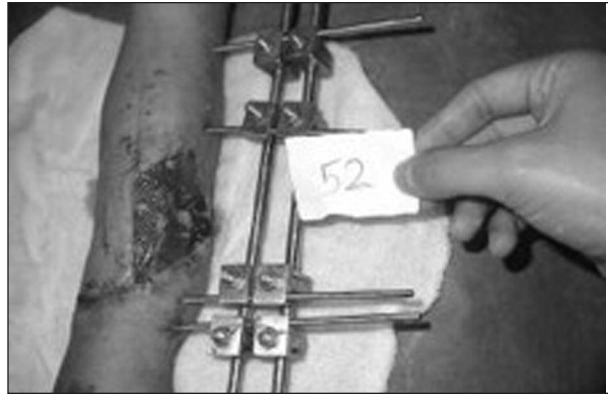The distal tip of the flap failed to take, and therefore, was advanced a week later. She made a good post-operative recovery.

Case 2: Taylor Spatial Frame and Local Flap

A 35-year-old woman was admitted with a compound, comminuted left distal tibial fracture. She had undergone initial stabilization with an ankle, bridging, monolateral, external fixator (Figure 7).

She underwent initial examination under anesthesia and debridement of the wound. The decision was made to perform an acute shortening and application of a Taylor Spatial Frame. A fasciocutaneous flap was fashioned to cover the soft tissue defect at the same time as the frame was applied (Figure 8).

Postoperative x-rays were taken and deformity correction was carried out using the online software accompanying the Taylor Spatial Frame (Figure 9).



Rajpura © 2010 Prehospital and Disaster Medicine

Figure 6—Top: Pre-operative photo showing soft tissue defect; Middle: Intra-operative photo while fashioning the local flap; Bottom: Post-operative photo after Ilizarov frame applied

She made a good post-operative recovery and began mobilizing with partial weight bearing.


Case 3: ORIF and Free Flap

A 16-year-old male was admitted with a compound left ankle fracture that was cleaned and had a cast applied in the field hospital. He underwent initial examination and debridement under anesthesia, which revealed a 15 x 6 cm defect medially. This was repeated two days later. The location and size of the defect necessitated a free flap to gain tissue cover. A free Rectus Abdominis flap and open reduction and internal fixation of the fracture was carried out three days later (Figure 10). The flap took successfully and the patient went on to make a good recovery.



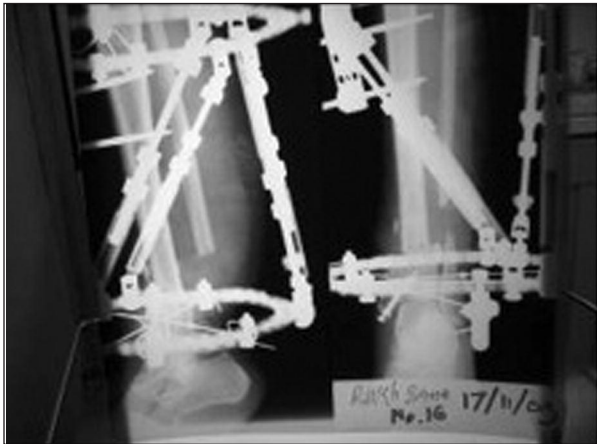
Rajpura © 2010 Prehospital and Disaster Medicine

Figure 7—Pre-operative x-rays, Right: Soft tissue defect on the anteromedial aspect of the left leg.



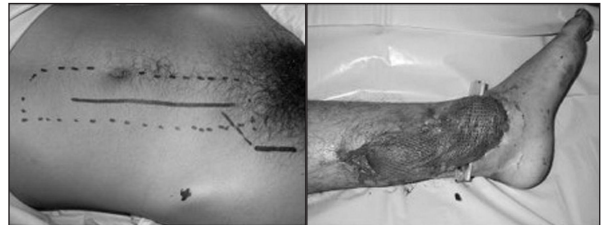
Rajpura © 2010 Prehospital and Disaster Medicine

Figure 8—Left: Pre-operative planning of the FC flap, Right: Post-operative photo showing Taylor Spatial Frame and Fasciocutaneous Flap



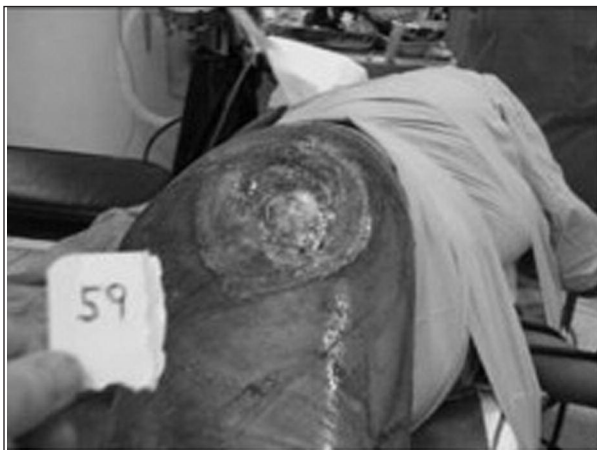Rajpura © 2010 Prehospital and Disaster Medicine

Figure 9—Post-operative x-rays prior to final correction using computer aid



Rajpura © 2010 Prehospital and Disaster Medicine

Figure 10—Left: Pre-operative planning for rectus abdominis flap, Right: Post-operative result



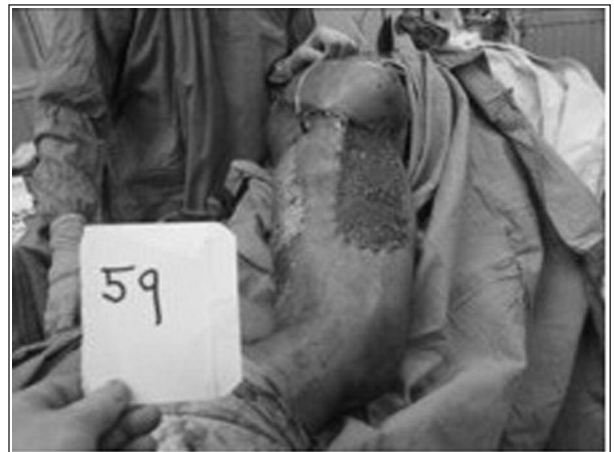Rajpura © 2010 Prehospital and Disaster Medicine

Figure 11a—Pre-operative appearance of the pressure sore

Case 4: Myocutaneous Flap

A 60-year-old woman was admitted to the unit after having undergone a left above knee amputation secondary to crush injury. This had rendered her bed bound and she went on to develop a grade IV pressure sore over her right greater trochanter. She underwent initial examination and debridement under anesthesia, which left a 15 x 10 cm defect over the trochanteric area (Figure 11a).

She underwent repeat examination under anesthesia three days later and the decision was made to carry out a



Rajpura © 2010 Prehospital and Disaster Medicine

Figure 11b—Post-operative appearance of the pressure sore

rotational flap to gain soft tissue cover. A Tensor Fascia Lata flap was carried out two days later (Figure 11b).

Drains and stitches were removed after two weeks. The flap had taken successfully at this point and the patient was discharged three days later.

Complications

No anesthetic complications were encountered during the 12 days. Early post-operative surgical complications mainly were related to plastic surgical procedures carried out to provide soft tissue cover to compound fractures. This included one fasciocutaneous flap that necrosed completely and required revision, and a further three fasciocutaneous flaps whose distal tips underwent necrosis. Two of these required surgical debridement and advancement, which were successful. Two amputations, one below knee, and one symes amputation, suffered wound breakdown requiring

operative debridement. Split skin grafting was required to gain wound closure for the below-knee amputation.

Discussion

The aim of this project was to limit both morbidity and mortality in survivors of the earthquake who had suffered severe limb trauma through limb salvage operations and by addressing the third peak in mortality seen in trauma patients as described by Trunkey *et al.*⁴ This peak is thought to be due to late complications of the injuries sustained, such as sepsis. This especially was relevant in the patient population due to the high proportion of open fractures. In order to accomplish the aims, resources were mobilized from the UK. The self-reliant teams that travelled to Pakistan consisted of plastic/orthopedic surgeons, junior medical staff, anesthetists as well as scrub staff and operating room staff. The specialist equipment required by the surgeons/anesthetists and disposables were brought by the teams in order to avoid demand on already scarce local resources.

As demonstrated by the case mix presented, a joint ortho-plastic approach was key to the success of this mission. Having arrived four weeks after the earthquake struck, the majority of the cases encountered were infected, complex, and/or open fractures that had only received initial first aid treatment and primitive stabilization. Therefore, in order to fulfill the objective of limb salvage, a team specialized in limb reconstruction, (both bony and soft tissue) was essential. Of the 66 patients with bony injuries, only four had to undergo fresh amputation and 11 revisions of amputations were carried out. Therefore, the amputation rate was 6% (overall 22% including revisions amputations). Without surgeons skilled in limb reconstruction using ring fixators and soft tissue reconstruction, a possible further 20 patients would have required amputation.

Many individual surgeons had arrived before the team and had done an admirable job. Unfortunately, due to the limited resources available, complexity of the injury patterns encountered, and perhaps the lack of experience in some cases, some cases were encountered that had been managed less than ideally, e.g., transphyseal medullary nail fixation of fractures and inappropriate flaps with loss of valuable tissue. Therefore, a team-based multidisciplinary approach, along with specialized equipment such as ring fixators, was necessary to tackle the complex cases encountered, which would have required tertiary care anywhere in the world.

Mobilizing teams such in the immediate aftermath logistically is challenging, and it took four weeks to gather local information, setup a base and collect the essential equipment for the team in this project. As suggested by Laverick *et al.*, a central register of future volunteers, including surgeons and allied health professionals that would be willing and available at short notice, would enhance the response time in future efforts.¹¹ In light of the large proportion of open fractures with soft tissue loss encountered, earlier arrival especially could have helped this subset of patients by providing quicker appropriate soft tissue management, potentially reducing rates of osteomyelitis that

complicates further fracture management and significantly delays recovery. With the use of ring fixators, more complex injuries that had to undergo early amputation potentially may have been salvageable.

All of the operative work was performed by members of the team. However, the team did receive anesthetic and nursing (scrub and ward) backup from local staff. This balance was essential; as it gave team clinical autonomy but also helped provide peri-operative care for patients and to train the local staff that were not always familiar with the surgical techniques used.

However, this setup did lack physiotherapists and occupational therapists, which will have hampered the ultimate outcomes of the management. The team has now recruited such allied health professionals to help with post-operative management during future projects.

Another limitation of this setup was provisions for follow-up of these patients. The majority of the patients had been transferred from villages to the north of Islamabad that stood in ruins. Once discharged from the unit, they were transferred to emergency housing camps that had been setup around Islamabad. Following the first two teams, three smaller teams were sent on a weekly basis to staff the trauma unit and provide continued care for the remaining patients and short-term follow-up for the discharged patients. Unfortunately, in the longer term, it is estimated that half of the patients have been lost to follow up, as they no longer had fixed residences where they could be contacted.

Starting April 2006, a further three teams were sent on a monthly basis to Ayub Medical College Hospital in Abbottabad in the North West Frontier Province. This is located in the region from which the majority of the patients originally came. Their aim was to attempt to locate and provide long-term treatment and follow-up for earthquake victims, irrespective of whether they originally were not treated by the team. Efforts are continuing to setup a limb reconstruction unit in Abbottabad in conjunction with local medical staff.

Conclusions

Cultural sensitivity and local infrastructure analysis will assist a medical team in providing appropriate surgical interventions. Hence, collaboration with the local teams who know the people, the area, and the problems was essential to this effort. A multidisciplinary team effort in an earthquake situation is much more likely to succeed in limb salvage. The majority of the injuries involved limbs and were open with soft tissue loss.

The number of cases requiring surgical intervention is likely to be more than expected, and the team should be prepared to work flexibly, and in collaboration with other healthcare professionals. It also is important to have a designated lead person who can liaise with the local officials and may be familiar with local circumstances.

The long-term welfare of the patients also must be considered and arrangements must be made to have the patients followed-up safely. It is possible that techniques used by the specialist teams are not familiar to the local medical community.

References

1. US Geological Survey: Northern Pakistan Earthquake of 8 October 2005. Available at <http://earthquake.usgs.gov/cqcenter/eqarchives/poster/2005/20051008.php>. Accessed 18 May 2008.
2. The International Federation of Red Cross and Red Crescent Societies: Pakistan Earthquake FACTS AND FIGURES SHEET. Available at <http://www.ifrc.org/Docs/pubs/disasters/pakistan-earthquake/facts-figures-1006.pdf>. Accessed 18 May 2008.
3. Baker CC, Oppenheimer L, Stephens B, *et al*: Epidemiology of trauma deaths. *Am J Surg* 1980;140(1):144–150.
4. Trunkey DD: Trauma. Accidental and intentional injuries account for more years of life lost in the US than cancer and heart disease. Among the prescribed remedies are improved preventive efforts, speedier surgery and further research. *Sci Am* 1983;249(2):28–35.
5. Ahmad MA, Naqui SZ, Shah N, *et al*: The Pakistan earthquake: A British trainee's experience. *Injury* 2006;37(6):567–569.
6. Bozkurt M, Ocguder A, Turktas U, Erdem M: The evaluation of trauma patients in Turkish Red Crescent field hospital following the Pakistan earthquake in 2005. *Injury* 2007;38(3):290–297.
7. Helminen M, Saarela E, Salmela J: Characterisation of patients treated at the Red Cross field hospital in Kashmir during the first three weeks of operation. *Emerg Med J* 2006;23(8):654–656.
8. Mulvey JM, Awan SU, Qadri AA, Maqsood MA: Profile of injuries arising from the 2005 Kashmir earthquake: The first 72 h. *Injury* 2008;39(5):554–560.
9. Siddiqi K: The Pakistan earthquake: A personal experience. *Lancet* 2006;367(9515):986.
10. Yasin MA, Malik SA, Nasreen G, Safdar CA: Experience with mass casualties in a subcontinent earthquake. *Ulus Travma Acil Cerrahi Derg* 2009;15(5):487–492.
11. Laverick S, Kazmi S, Ahktar S, *et al*: Asian earthquake: Report from the first volunteer British hospital team in Pakistan. *Emerg Med J* 2007;24(8):543–546.